

InterDry®

Moisture-wicking fabric
with antimicrobial silver


A proven approach for **real relief**:

Case studies and cutting tips for resolving
skin fold complications with InterDry®



In this guide, you'll find a series of case studies showing real-world examples of how InterDry can resolve skin fold complications quickly and effectively.

You'll also find helpful tips on how to cut InterDry for use in similar situations by clicking on the image at the bottom of each case study.



Case study: Under breast¹

Patient description:

92-year-old female patient presented for care of venous stasis ulceration.

Past treatments:

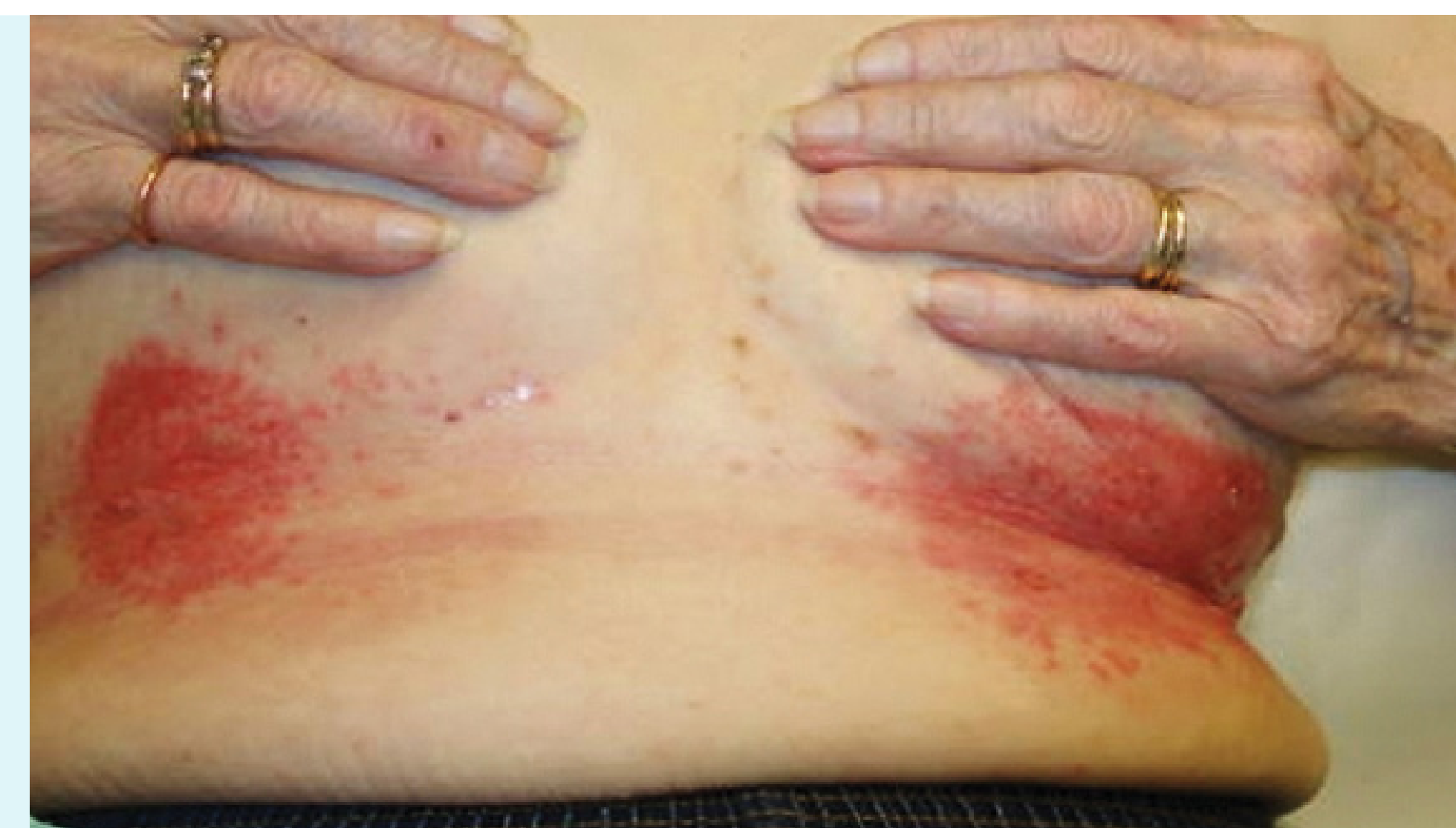Prescription antifungal powder applied twice daily and an oral antifungal administered daily for five days. The rash persisted and she was then treated with an antifungal cream applied two times daily for two weeks. Treatments were not effective.

InterDry protocol:

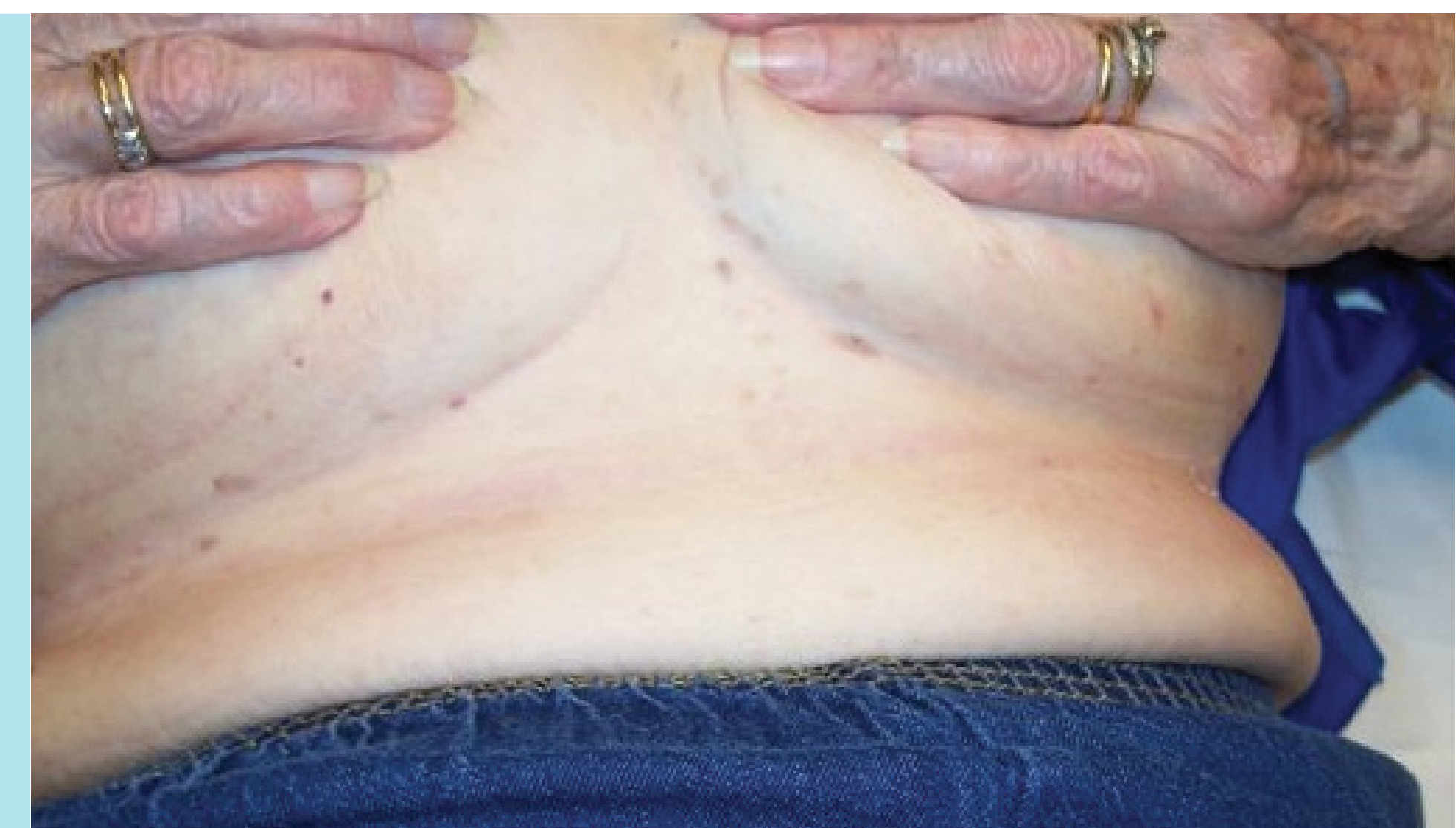Two strips of InterDry under each breast using a cotton sports bra to keep fabric in place.

Day 1:

Persistent, painful rash underneath her breasts. Candidal intertrigo with erythematous papules, satellite lesions, denudement, weeping and a musty odor.

**Outcome: Week 3**

Patient followed up weekly with improvement noted at week 2 and resolution of symptoms and rash by week 3.



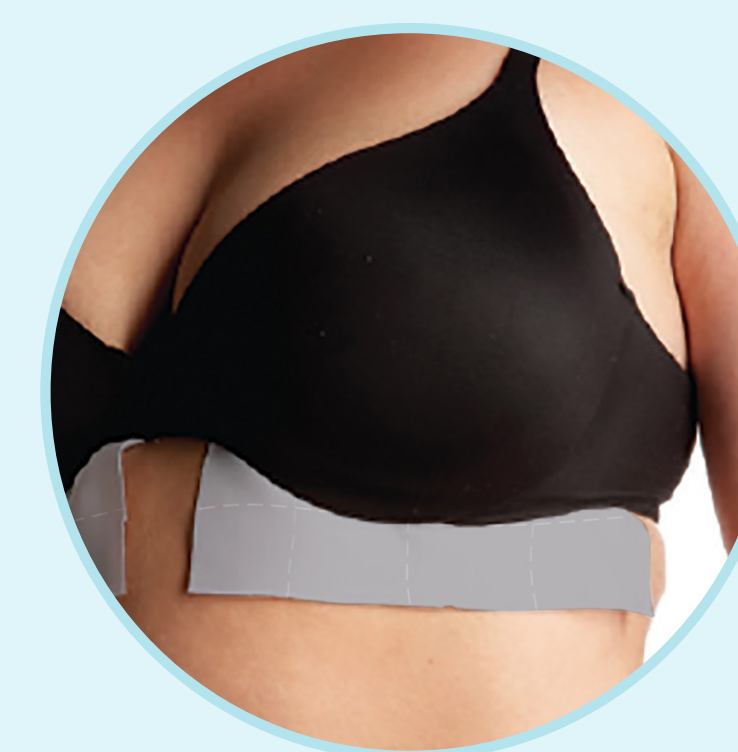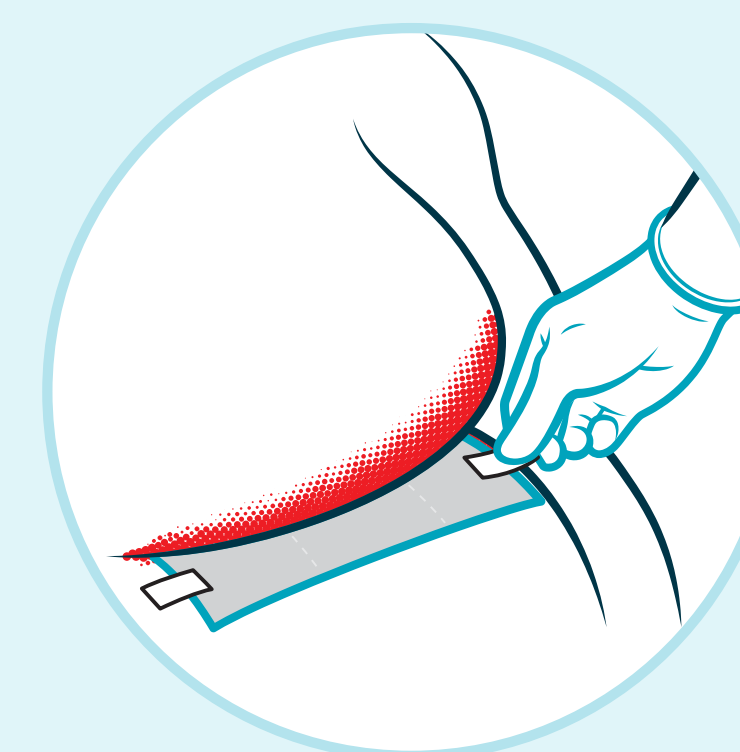
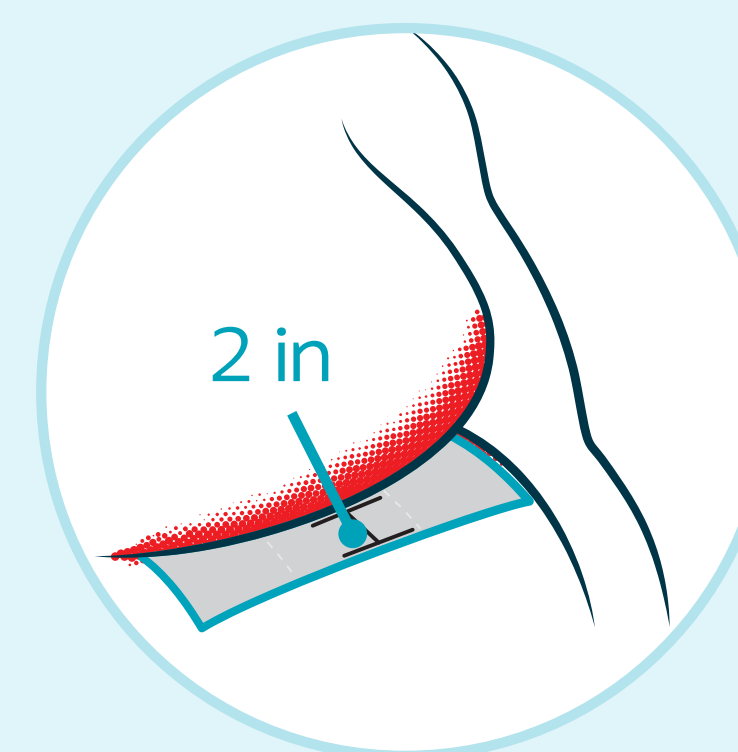
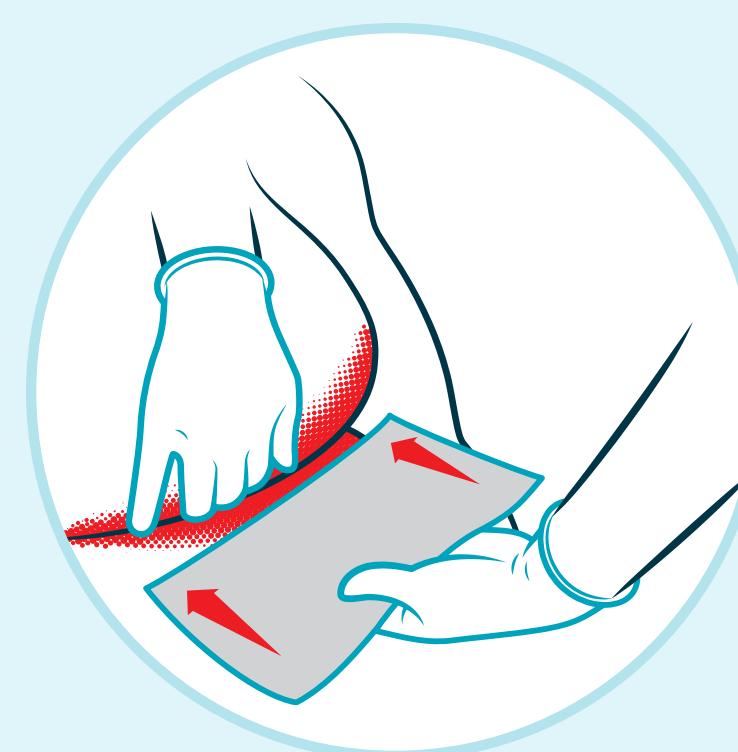
Cutting guide: Under breast



Rectangle

Ensure the rectangular piece of fabric covers the length of one breast to the other.

Important tips for using InterDry



1. Place a single layer of fabric in the skin fold. **Do not** use a double layer.
2. Leave at least **2 inches** (5 cm) exposed outside the skin fold.
3. Secure the fabric with skin-friendly tape as needed, depending on weight of the breast.
4. Change the fabric if soiled by blood, stool or urine.
5. Each piece of fabric may be used for up to **5 days**.
6. **Do not** use powders or creams under the fabric.

Case study: Abdomen²

Patient description:

80-year-old female, medical history includes obesity (5'3", 172 pounds, BMI 30.5), bilateral mastectomy, uncontrolled diabetes, hypertension, hyperlipidemia, and dementia.

Past treatments:

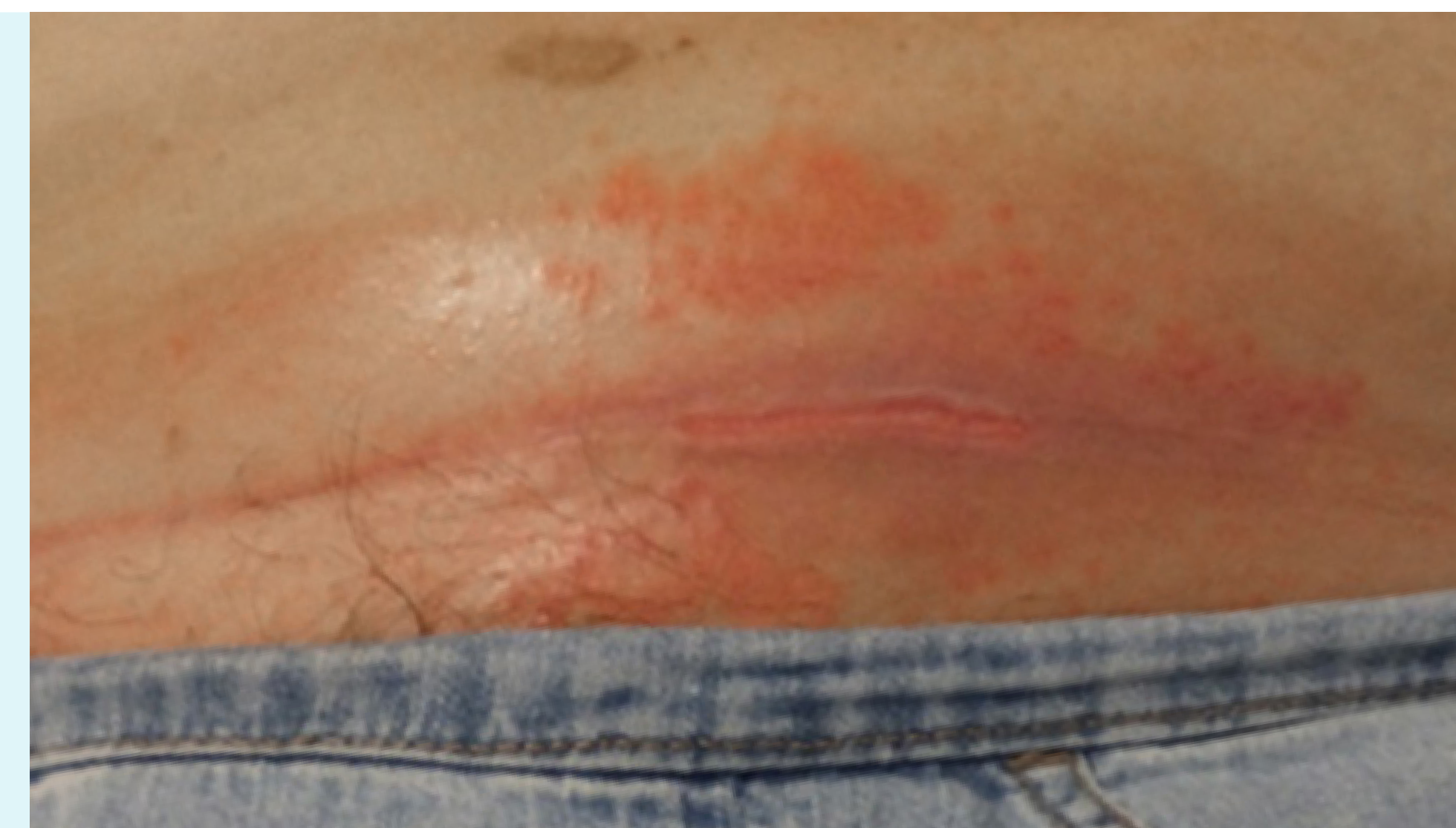No previous treatments.

InterDry protocol:

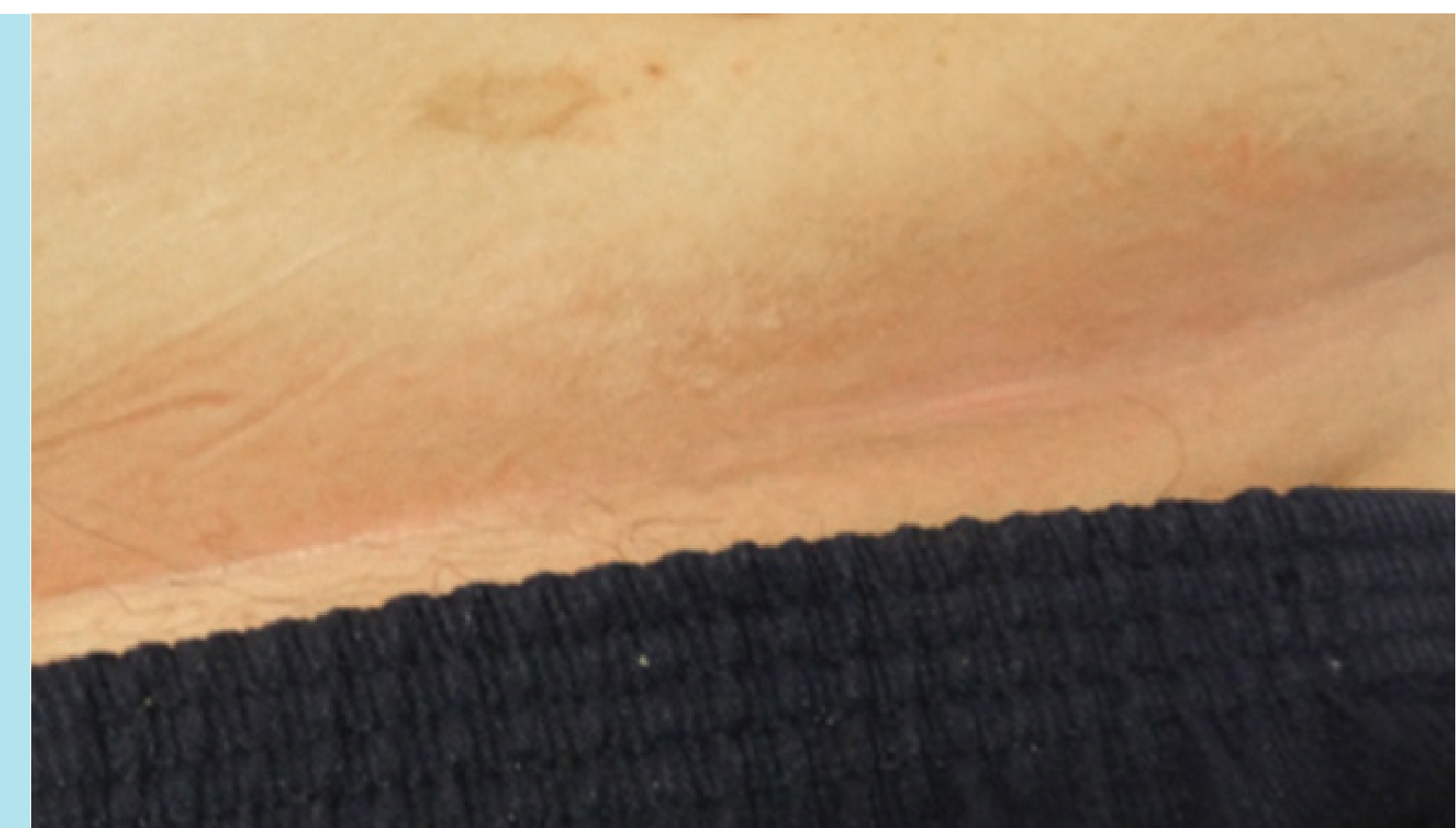InterDry was applied to manage the complications associated with skin folds: moisture, friction and fungal/bacterial organisms.

Day 1:

Severe case of ITD (erythema, maceration, satellite lesions, denuded skin at the base of the fold, odor and pain) underneath the large abdominal pannus.

**Outcome: Day 5**

Erythema, satellite lesions, odor, denuded area and pain under the pannus was 100% resolved.

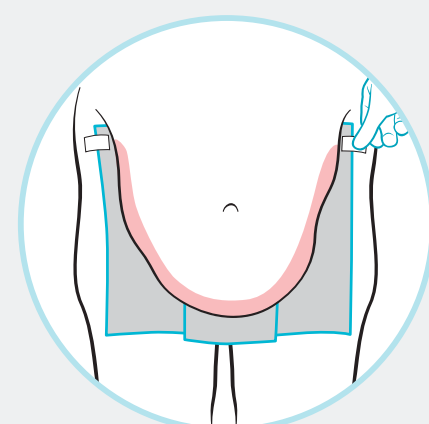
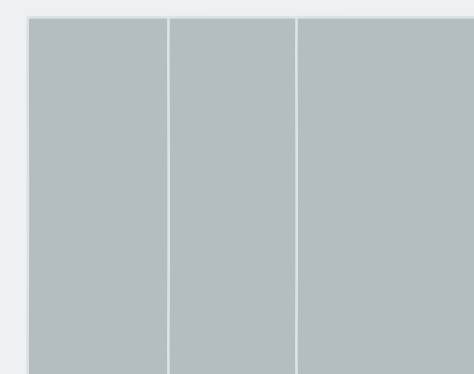


Cutting guide: Abdomen



Option 1: Rectangle

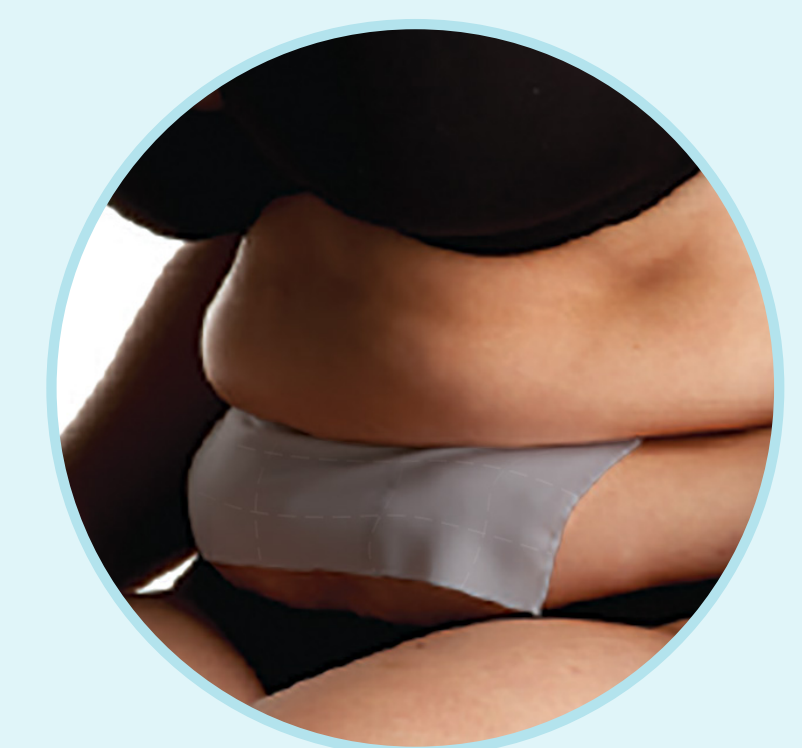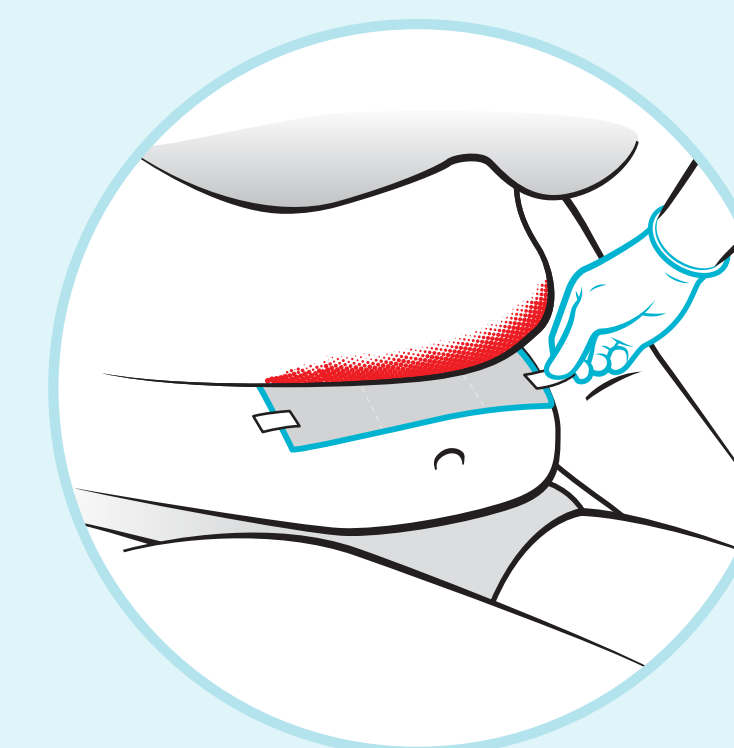
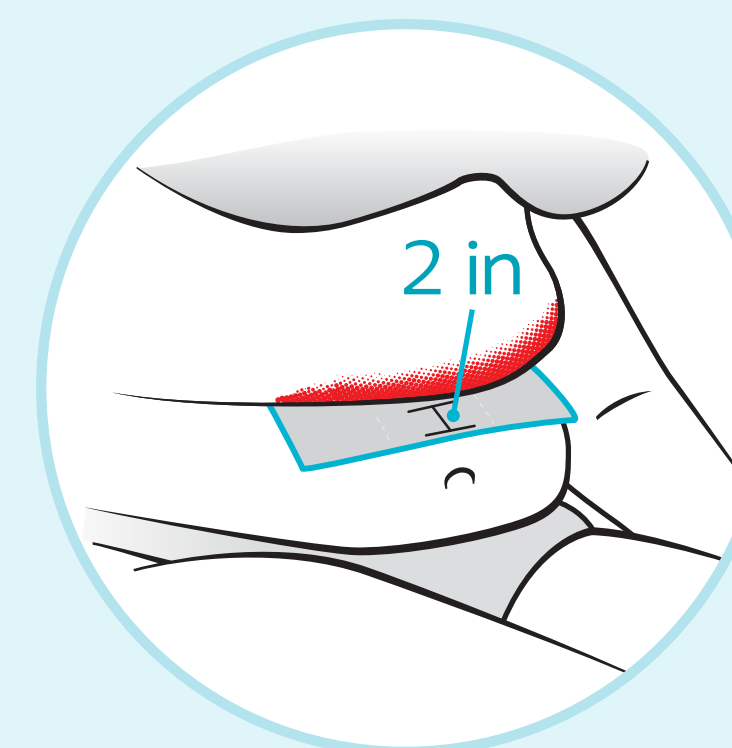
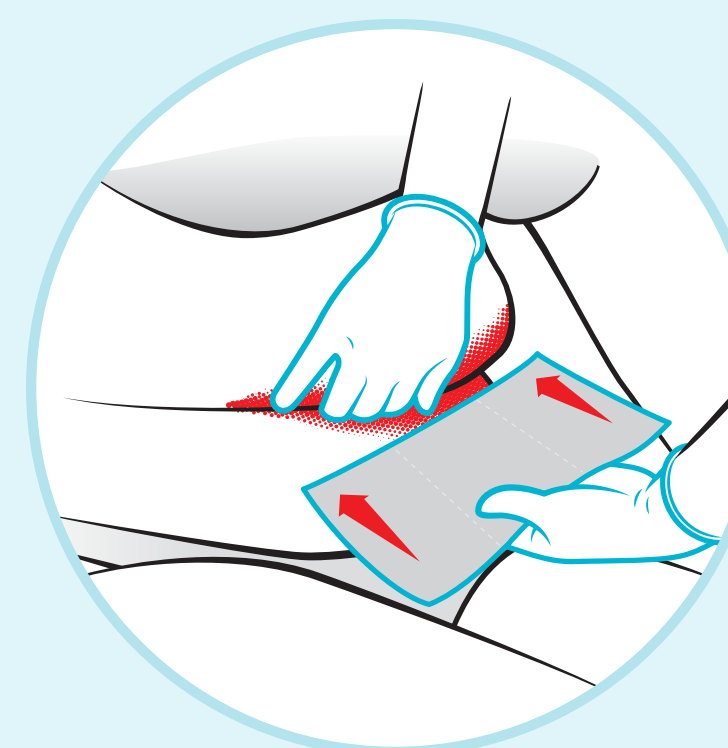
Cut the fabric to allow for the length and depth of the fold, leaving 2 inches (5 cm) of the product exposed to the air. Secure with skin-friendly tape as needed.



Option 2: Overlapping rectangles

A larger abdominal fold may require multiple vertical overlapping pieces of InterDry, with more than 2 inches (5 cm) of fabric exposed outside the skin fold. This will resemble an apron. Use skin-friendly tape to secure.

Important tips for using InterDry



1. Place a single layer of fabric in the skin fold. **Do not** use a double layer.
2. Leave at least **2 inches** (5 cm) exposed outside the skin fold.
3. Secure the fabric with skin-friendly tape.
4. Change the fabric if soiled by blood, stool or urine.
5. Each piece of fabric may be used for up to **5 days**.
6. **Do not** use powders or creams under the fabric.

Case study: Skin-to-device³

Patient description:

A 42-year-old male presented with chronic, recurrent venous dermatitis to the lower extremities and venous insufficiency ulcers.

Compression wraps were used to treat the venous insufficiency ulcers, but this resulted in new ulceration due to maceration caused by excessive sweating.

Past treatments:

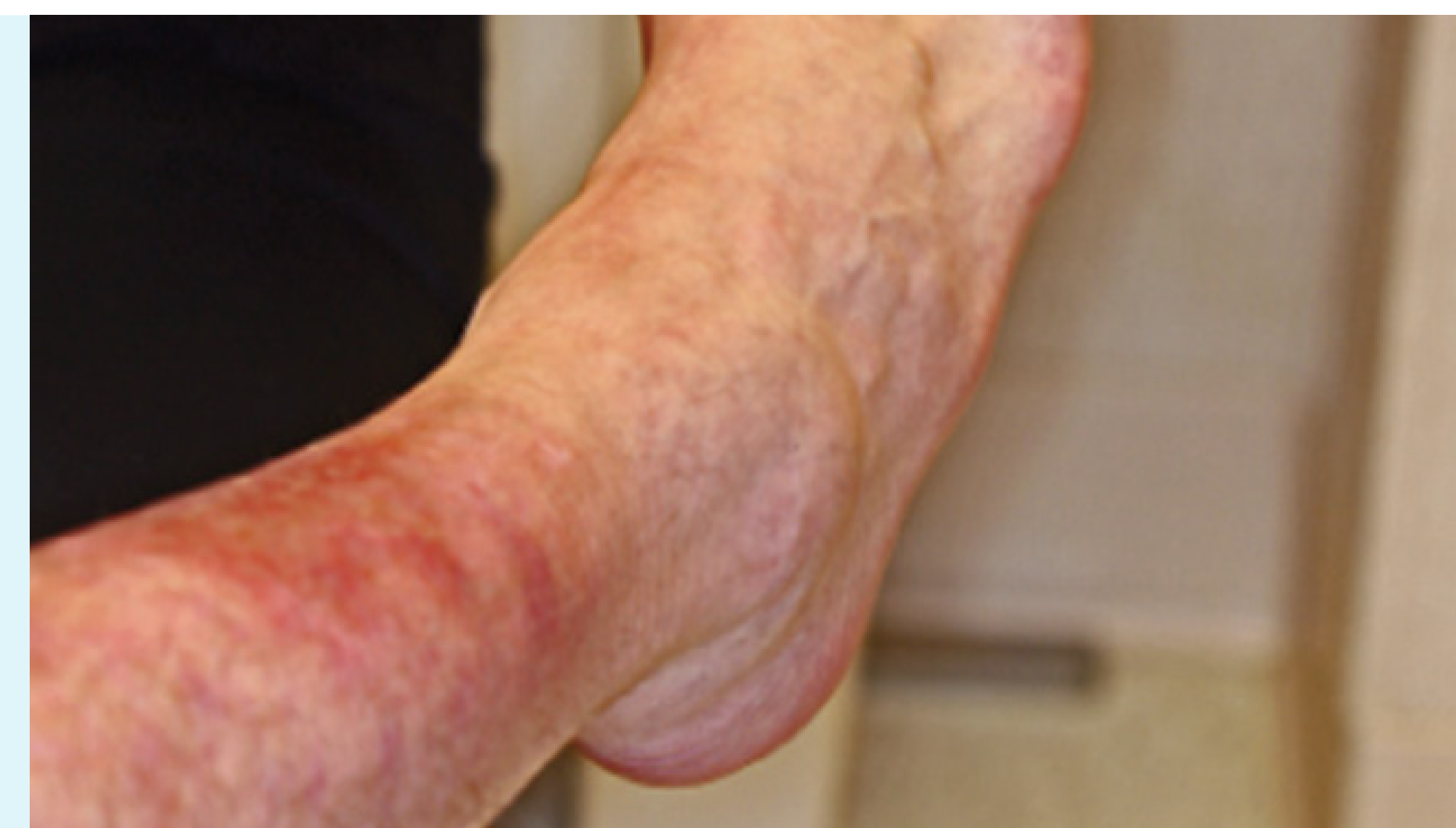No previous treatments.

InterDry protocol:

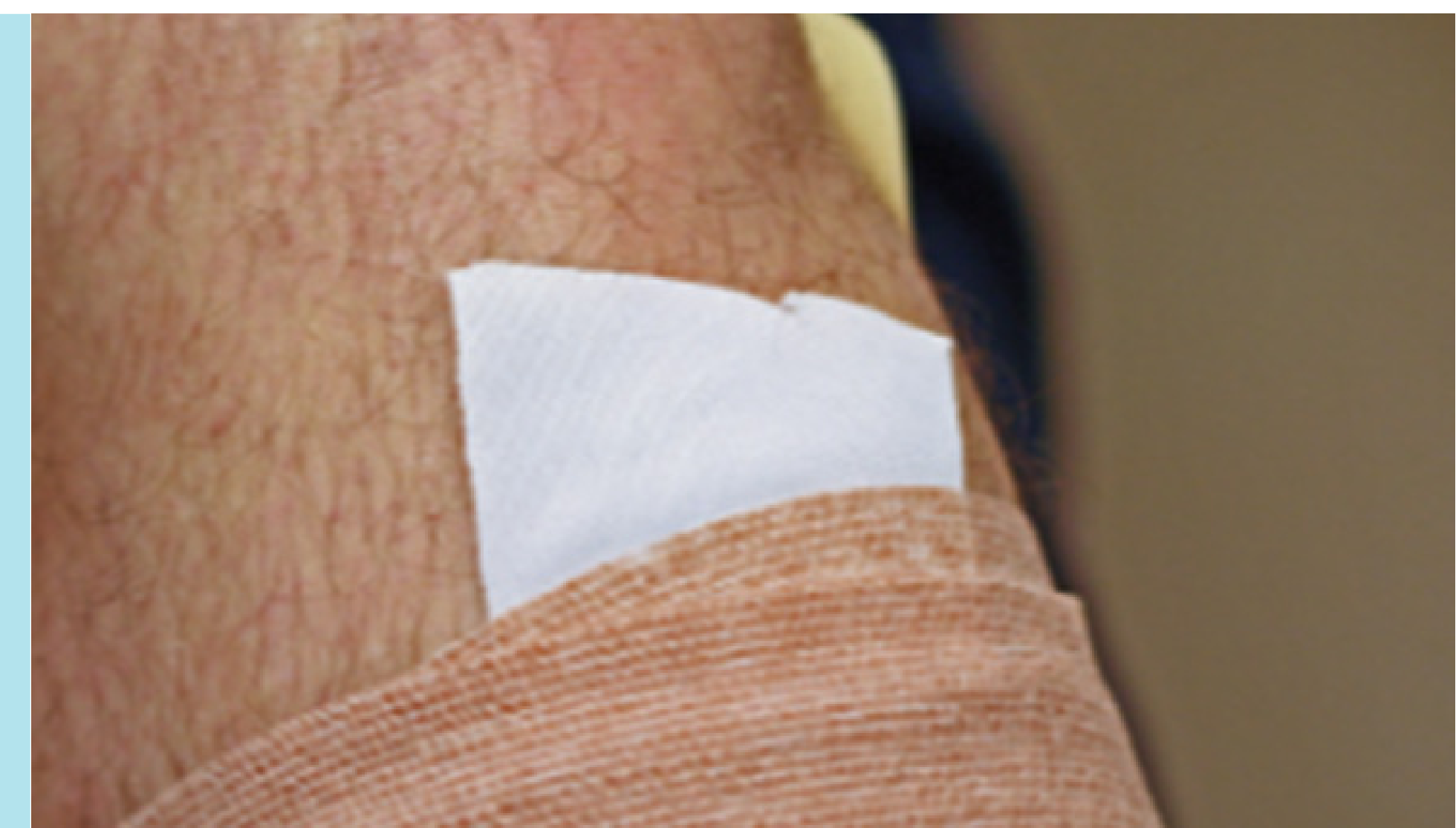InterDry was used under the compression wrap to wick away excessive moisture, resulting in elimination of the maceration and venous dermatitis.

Day 1:

Venous dermatitis and a new ulceration due to maceration caused by excessive sweating.

**Outcome:**

Elimination of the maceration and venous dermatitis.



Cutting guide: Skin-to-device*

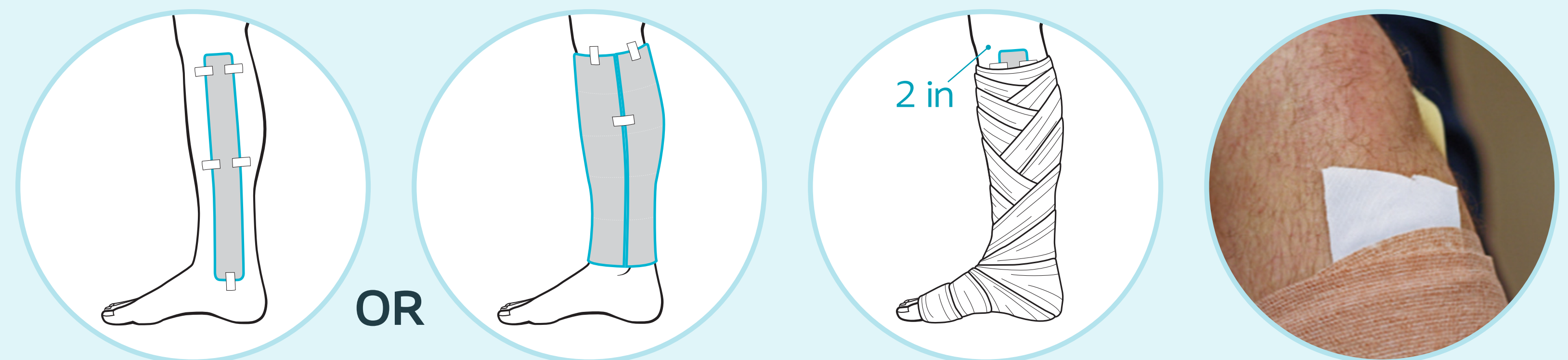


Long rectangle

Cut a strip of InterDry to match length of compression wrap from ankle to knee. Secure with skin-friendly tape until the compression wrap is applied and can hold the InterDry in place. If using multiple pieces of fabric, do not overlap.

InterDry can also be used with a variety of other removable medical devices, including heel suspension boots, cervical collars, trach ties, and more.

Important tips for using InterDry



1. Place a single layer of fabric under the medical device.
Do not use a double layer.
2. Leave at least **2 inches** (5 cm) of the fabric exposed outside the removable medical device or compression wrap.
3. Secure the fabric with skin-friendly tape.
4. Each piece of fabric may be used for up to **5 days**. If used under compression wrap, InterDry changes will be dictated by the schedule for next compression wrap application.
5. **Do not** use powders or creams under the fabric.

*InterDry should not be placed directly onto an open wound.

Ready to get started using InterDry?

Talk to your wound care specialist to learn if InterDry is on formulary at your facility.

Looking for more information on how to use InterDry?

[Click here](#) to see an application video with both skin-to-skin and skin-to-device examples.

[Click here](#) to see our full InterDry cutting guide with 11 skin-to-skin and skin-to-device use cases.

1. Vorbeck, E. Evaluation of a skin fold management textile with antimicrobial silver complex in a variety of case studies. Mayo Health System, Minnesota.
2. Haberer P. When ITD hits home: best practice tips for using a moisture-wicking fabric with silver for intertriginous dermatitis. 7th Annual Symposium on Advanced Wound Care, Southeast Region of the WOCN society. September, 2015
3. Freyberg J, Netsch D, Tessling J. Moisture management challenges for the WOC nurse. Presented at the 39th WOCN® Society Annual Conference, June 2007. Presented at the 22nd Annual Clinical Symposium on Advances in Skin and Wound Care, October 2007.

For illustrative purposes only. This information is not intended to constitute medical or business advice or in any way replace the independent medical judgment of a trained and licensed physician with respect to any patient needs or circumstances and may not be representative of all patient outcomes. Actual amounts, performance, outcomes, and experience may vary. Refer to product labeling for complete instructions including product uses, ingredients, purpose, warnings, precautions and other information.

Coloplast was founded on passion, ambition, and commitment. We were born from a nurse's wish to help her sister and the skills of an engineer. Guided by empathy, our mission is to make life easier for people with intimate healthcare needs. Over decades, we have helped millions of people live more independent lives and continue to do so through innovative products and services. Globally, our business areas include Ostomy Care, Continence Care, Advanced Wound Care, Interventional Urology and Voice and Respiratory Care.

Coloplast United States

Minneapolis, MN 55411 / 1-800-533-0464 / www.coloplast.us

Coloplast Canada

Oakville, ON L6H 0H2 / 1-866-293-6349 / www.coloplast.ca

Coloplast and the Coloplast logo are trademarks of Coloplast A/S.

© 2025-03 Coloplast A/S. All rights reserved. PM-37106