


A pathway for
treating a person with a:

Surgical wound dehiscence



An evidence-based step-by-step guide
developed by clinicians for clinicians



Coloplast

Developed by clinicians for clinicians

This pathway was developed with feedback and input from over 2200 health care professionals in the field of wound care. It offers a unique evidence-based approach to managing surgical wound dehiscence and lets you put the latest evidence in wound care to use in real life.

Authors:

Terry Swanson, Nurse practitioner, Australia; Dr. Caroline Dowsett, United Kingdom; Dr. Jose Ramon March Garcia, Spain; Emily Greenstein, Nurse practitioner, USA; Dr. David Keast, Canada; Dr. Long Zhang, China; Dr. Hester Colboc, France

Clinical references:

1. World Union of Wound Healing Societies (WUWHS) Consensus Document. Surgical wound dehiscence: improving prevention and outcomes. Wounds International, 2018.
2. Brown BC, McKenna SP, Siddhi K et al (2008) The hidden cost of skin scars. J Plast Reconstr Aesthet Surg 61(9): 1049-58.
3. Ziolkowski N, Kitto SC, Jeong D (2019) Psychosocial and quality of life impact of scars in the surgical, traumatic and burn populations. BMJ Open 9: e021289.
4. Sandy-Hodgetts K et al (2020) International best practice recommendations for the early identification and prevention of surgical wound complications. Wounds International. Available online at: www.woundsinternational.com.

Take a shorter way to wound healing

By following the steps in this pathway, you can provide an optimal healing environment for surgical wound dehiscence and reduce the risk of complications that could lead to delayed healing or worse.

Any advice included here needs to work in conjunction with your local protocols and your individual scope of practice.



Whenever a QR icon appears you can scan the correlating QR code at the bottom of the page.



To access helpful tools, scan the blue QR codes.



To dive deeper into subjects, scan the light blue QR codes.




The guidance provided in this book, is best understood in combination with the detailed guidance available to you in [The Wound Care Pathway](#). Whenever the book icon appears you can look up further information there.

Scan to download
The Wound Care Pathway



What is a surgical wound dehiscence?

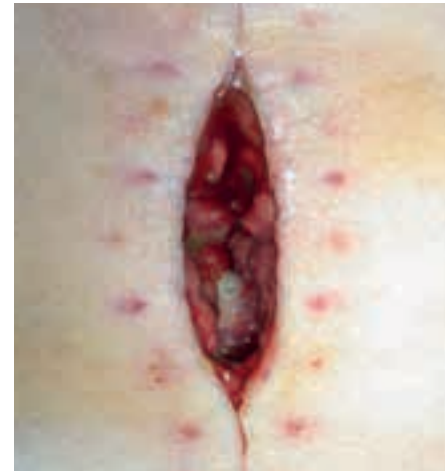Surgical Wound Dehiscence  is the separation of the margins of a closed surgical incision that has been made in the skin. It will sometimes involve an exposure or protrusion of underlying tissue, organs or implants. The separation may occur at a single or multiple regions, or involve the full length of the incision, and may affect some or all tissue layers.¹

The most common causes can be categorised as:

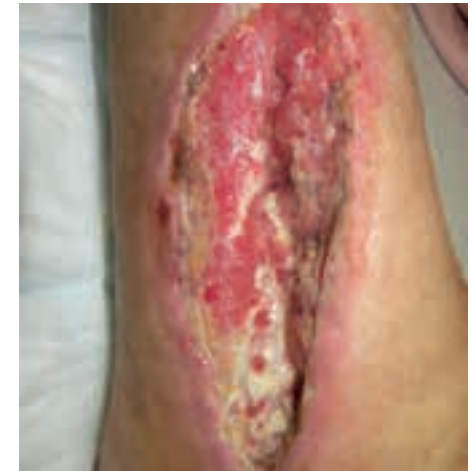- Technical issues with the closure (e.g. unravelling of sutures)
- Mechanical stress (e.g. coughing can cause wound incision to break down)
- Disrupted healing (e.g. due to comorbidities or infection)

Be aware, that a surgical wound dehiscence generally occurs between 4-14 days after surgery but can also occur up to 30 days after. A dehiscenced incision may, or may not, display clinical signs and symptoms of infection.¹

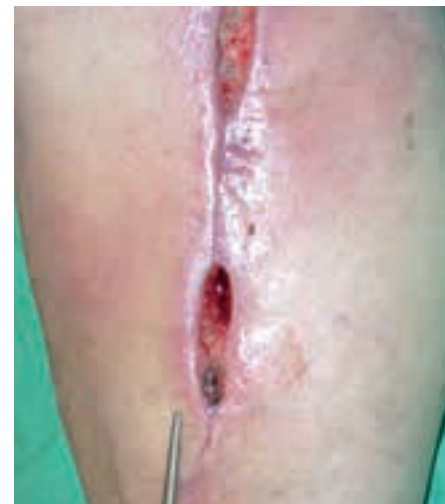What does it look like?



Surgical wound dehiscence with exposure of underlying tissue and implant



Surgical wound dehiscence involving full length of incision and affecting all tissue layers





Surgical wound dehiscence occurring at multiple regions

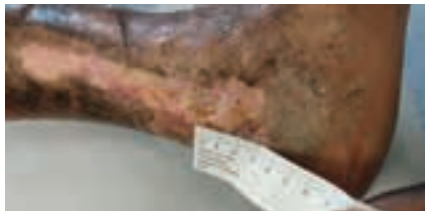

Scan to learn more about
surgical wound dehiscence

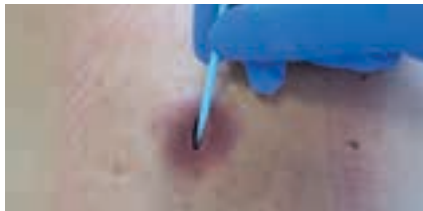Step 1

How to **assess** a surgical wound dehiscence


- First, you should conduct a holistic patient assessment :
- Look into medical/surgical history
 - Assess current health, lifestyle, medication, pain, psychosocial status
 - Understand what led up to dehiscence – coughing, vomiting, trauma, purulent drainage, infection, etc.
- Next assess the dehiscence, by using a validated assessment tool like the Triangle of Wound Assessment :
- Measure length, depth and appearance
 - Check for undermining, tunnelling, exposure of medical material
 - Check for oedema, warmth, pain
 - Assess wound exudate
 - Check for signs of infection
 - purulent exudate indicates infection is present



Measure length and width of dehiscenced wound




Probe to measure wound depth

- Categorize the surgical wound dehiscence (SWD) according to the WUWHS grading system  from 1 / 1a, to 4 / 4a.¹

Grading system	Descriptors
Grade 1	Dermal layer only involved – No visible subcutaneous fat No clinical signs and symptoms of infection
Grade 1a	Dermal layer only involved – No visible subcutaneous fat Clinical signs and symptoms of infection present
Grade 2	Subcutaneous layer exposed; fascia not visible No clinical signs and symptoms of infection
Grade 2a	Subcutaneous layer exposed; fascia not visible Clinical signs and symptoms of infection present
Grade 3	Subcutaneous layers and fascia exposed No clinical signs and symptoms of infection
Grade 3a	Subcutaneous layers and fascia exposed Clinical signs and symptoms of infection present
Grade 4	Any area of fascial dehiscence with organ space, viscera, implant or bone exposed No clinical signs and symptoms of infection
Grade 4a	Any area of fascial dehiscence with organ space, viscera, implant or bone exposed Clinical signs and symptoms of infection present



Keep in mind, that with surgical wound dehiscence it is important to be aware of how signs and symptoms may present in a range of skin tones  (i.e. colouration).



Scan to access
The Triangle of Wound Assessment



Scan to access
the grading chart for SWD
(page 18)



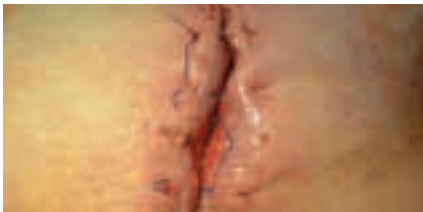Scan to learn more about
skin tone bias in health care

How to **diagnose** surgical wound dehiscence

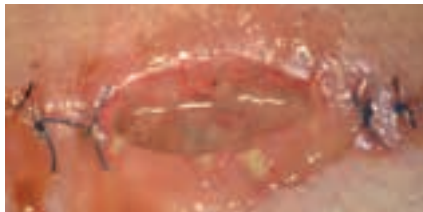- First you should diagnose the severity of the dehisced surgical wound by grading it from 1/1a-4/4a.
- Then assess for signs of infection.

You should check for infection by looking for:

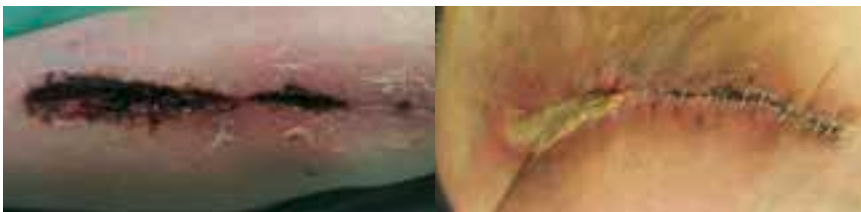- Pain, tenderness or oedema
- Purulent discharge
- Local temperature changes and/or fever



A dehisced surgical wound with no clinical signs of infection.




A dehisced surgical wound presenting several signs of infection; Pain, odor, redness and pus



Dehisced surgical wounds presenting two common signs of local infection = Redness and oedema



Step 2

How to develop a **treatment & care plan**

- Always develop a holistic care plan that involves the patient in both development and implementation. Review patient expectations and outcomes and potential limitations.
 - Let your treatment plan be determined by the severity of the dehiscence and the absence or prevalence of infection. If infection is already present you should treat the wound as a priority.
 - Make sure you take all factors into account as you plan:
 - Prevention of infection and deterioration
 - Infection treatment
 - Management of risk factors of systemic infection
 - Frequency of dressing changes, cleansing and debridement
 - Maintenance of body temperature and adequate oxygenation
 - Pain management – well controlled pain
 - Nutrition
 - Post-Operative Care
 - Surveillance and reporting
-  **Keep in mind**, that signs of inflammation at the incisional site, e.g. warmth, erythema, oedema, discolouration and pain, are normal during the first few days after surgery, and do not necessarily indicate infection.


Step 3

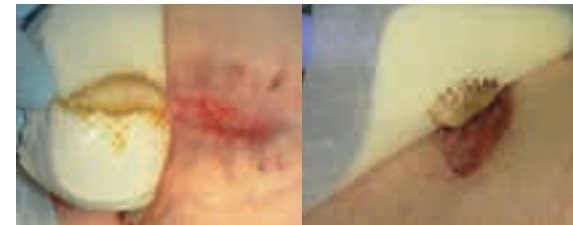How to **manage** surgical wound dehiscence

- First, prepare the wound bed by cleansing and debriding the wound to remove debris and necrotic or indolent tissue. 
- You should use every dressing change to assess the wound again. Use a validated assessment tool to conduct a formal reassessment on a regular basis until wound is fully healed.
 - Reduction of wound size is a key indicator of healing
 - If wound is infected monitor signs and symptoms based on IWII Infection Continuum & Management Guide 
 - After the wound bed preparation, some wounds can be sutured for the second time to heal, if this is being considered, refer back to surgeon
- Consider using NPWT for highly exudating wounds and for wound dehiscences, that are categorized as grades 3 & 4. As healing progresses, step down from advanced therapies (i.e. when exudate decreases or wound improves consider stepping down from NPWT to standard dressing).

Step 4

How to **choose dressing** & additional therapy


- To provide an optimal healing environment, choose a dressing that is appropriate for the level of exudate, size of wound and skin type. The dressing type may need to be changed as healing progresses, or if there is no progress in the wound over a two-week period.
- Make sure the dressing is able to conform to the wound bed – it should leave no gap between dressing and wound bed in order to effectively manage exudate, moisture and bacterial balance. 



Wound bed conforming dressings used on surgical wound dehiscence



Gelling fiber used on a surgical wound dehiscence

- Only choose dressings that are atraumatic upon removal. You should be able to easily remove it intact, and not cause further damage to the wound bed or periwound skin.
-  **Keep in mind!** If you are inserting more than 1 dressing, the number of dressings needs to be documented on the dressing or in the chart and all should be removed at the next dressing change.
- If you suspect infection use a dressing with antimicrobial properties.



Scan to learn more about
managing surgical site infection

Step 5

How to **monitor** progression

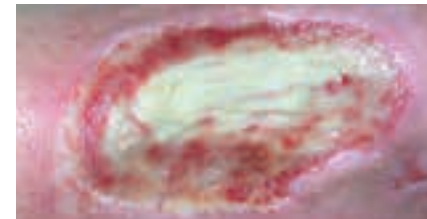
- You should conduct reassessments at time intervals that are appropriate for the severity of wound.
- As part of your holistic care plan involve your patient in monitoring and managing the surgical wound dehiscence. Your patient education should include:
 - How to detect signs and symptoms of infection
 - Reducing risk factors – how to avoid putting additional stress on the incision
 - Advice about activity levels
 - Scar tissue management and cosmetic implications/effects
 - Instruction to contact HCP if symptoms occur or patient deteriorates
- Monitor for signs of oedema and manage swelling
- Assess vascular status if the dehiscence is on lower extremities
- Consider a re-evaluation near end of the process to confirm healing and to evaluate scarring. Excess scar tissue can reduce mobility, delay return to normal activities and the visible aspect may affect the psychosocial wellbeing of the patient.²⁻⁴



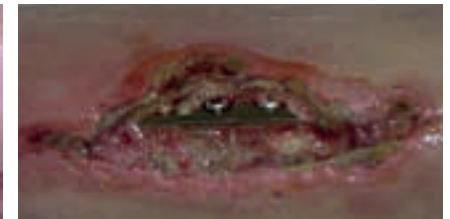Keep in mind! Communication among care team members is paramount. 📖

When to **refer or contact** a specialist

If organs, implants and/or bone is visible – make immediate referral back to surgeon.



Wound with bone visible



Wound with implant visible



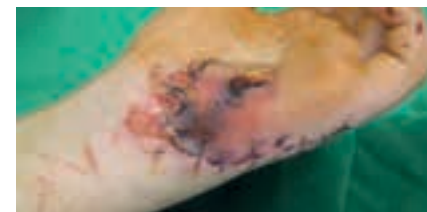If systemic infection is suspected refer to specialist.



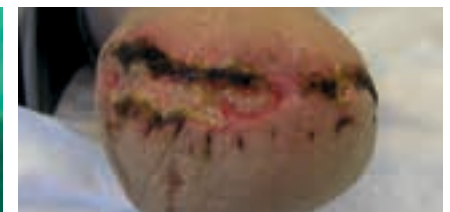If abscesses, large seromas or large haematomas are detected refer to specialist.



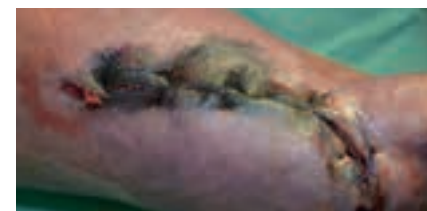If ischemia is suspected in a leg wound, refer for vascular assessment.



Wound with signs of spreading infection



Leg wound with signs of infection & ischemia



Leg wound with suspected ischemia

Glossary surgical wound dehiscence terms

Purulent Discharge – is a liquid that oozes from a wound, often thick with a milky look and texture that can vary in colour, from grayish or yellow to green or brown.

Abscesses – are swollen areas within body tissue, containing an accumulation of dead white blood cells and bacteria with tissue debris and serum.

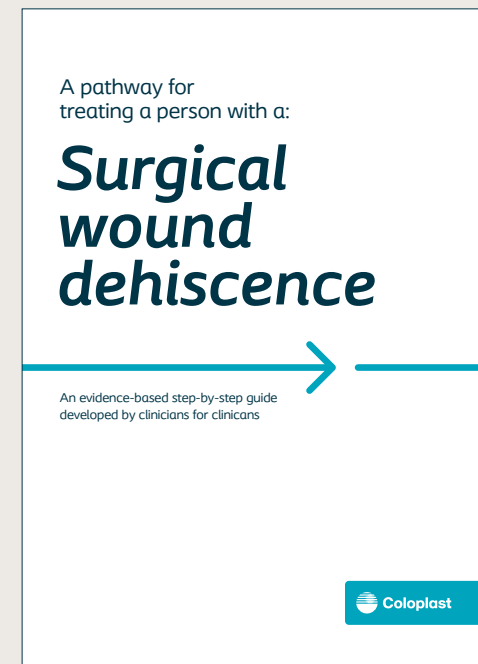
Seromas – are localized accumulations of serum fluid, occurring most commonly as a complication of a surgical procedure.

Haematoma – is an abnormal collection of blood outside of a blood vessel, causing swelling. A bruise is bleeding under the skin without swelling. The skin over a haematoma often feels spongy, rubbery and lumpy. Severity of haematoma depends on the size and depth. Refer patients if the haematoma is large, tense, painful, infected, over a joint or airway or is expanding.




Oedema – a build-up of fluid which causes the affected tissue to become swollen and can be localized or more general.



For a glossary of general wound care terms consult
The Wound Care Pathway



Hope you found this pathway useful!
For guidance on other **wound types**:





Coloplast A/S, Høtveddam 1
3050 Humlebaek, Denmark