


A pathway for
treating a person with a:

Venous leg ulcer



An evidence-based step-by-step guide
developed by clinicians for clinicians



Coloplast

Developed by clinicians for clinicians

This pathway was developed with feedback and input from over 2200 health care professionals in the field of wound care. It offers a unique evidence-based approach to managing venous leg ulcers and lets you put the latest evidence in wound care to use in real life.

Authors:

Terry Swanson, Nurse practitioner, Australia; Dr. Caroline Dowsett, United Kingdom; Dr. Jose Ramon March Garcia, Spain; Emily Greenstein, Nurse practitioner, USA; Dr. David Keast, Canada; Dr. Long Zhang, China; Dr. Hester Colboc, France


Clinical references:

1. Scottish Intercollegiate Guidelines Network, Elliott House, 8-10 Hillside Crescent, Edinburgh EH7 5EA www.sign.ac.uk
2. Evans R, Kuhnke JL, Burrows C, Kayssi A, Labreque C, O'Sullivan-Drombolis D, et al. Best practice recommendations for the prevention and management of venous leg ulcers. In: Foundations of Best Practice for Skin and Wound Management. A supplement of Wound Care Canada; 2019. 70 pp. Retrieved from: woundscanada.ca/docman/public/health-care-professional/bprworkshop/1521-wc-bpr-prevention-andmanagement-of-venous-leg-ulcers-1874e-final/file
3. de Maeseneer MG, Kakkos SK, Aherne T, Baekgaard N, Black S, Blomgreen et al. European Society for Vascular Surgery (ESVS) 2022 clinical practice guidelines on the management of chronic venous disease of the lower limbs. Eur J Vasc Endovasc Surg 2022; 63:184-267 (<https://doi.org/10.1016/j.ejvs.2021.12.024>)
4. <https://www.nationalwoundcarestrategy.net/lower-limb/>
5. Wounds UK (2021) Best Practice Statement: Addressing skin tone bias in wound care: assessing signs and symptoms in people with dark skin tones. Wounds UK, London. Available to download from: www.wounds-uk.com
6. Mehrara BJ, Greene AK. Lymphedema and obesity: is there a link? Plast Reconstr Surg. 2014 Jul;134(1):154e-160e. doi: 10.1097/PRS.0000000000000268. PMID: 25028830; PMCID:PMC4393748.
7. Rask-Madsen C, King GL. Vascular complications of diabetes: mechanisms of injury and protective factors. Cell Metab. 2013 Jan 8;17(1):20-33. doi: 10.1016/j.cmet.2012.11.012. PMID: 23312281; PMCID: PMC3546345.
8. Patton et al (2022) A meta-review of the impact of compression therapy on venous leg ulcer healing. International Wound Journal, Vol 20, Issue 2, p430-447.
9. European Society for Vascular Surgery (ESVS) 2022 Clinical Practice Guidelines on the Management of Chronic Venous Disease of the Lower Limbs. Eur J Vasc Endovasc Surg (2022) 63,184e267.

Take a shorter way to wound healing

By following the steps in this pathway, you can provide an optimal healing environment for venous leg ulcers and reduce the risk of complications that could lead to delayed healing or worse.

Any advice included here needs to work in conjunction with your local protocols and your individual scope of practice.



Whenever a QR icon appears you can scan the correlating QR code at the bottom of the page.



To access helpful tools, scan the blue QR codes.



To dive deeper into subjects, scan the light blue QR codes.



The guidance provided in this book, is best understood in combination with the detailed guidance available to you in [The Wound Care Pathway](#). Whenever the book icon appears you can look up further information there.

Scan to download
The Wound Care Pathway




What is a venous leg ulcer?

A venous leg ulcer is an open, often painful, sore in the skin on the leg below the knee. The ulcers usually develop on the inside of the leg and take more than 2 weeks to heal.

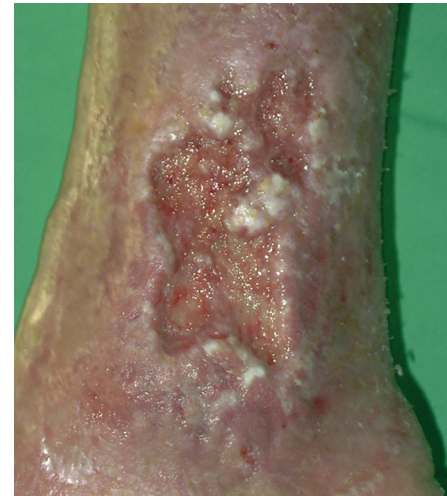Most common cause

Venous leg ulcers are caused by venous hypertension, such as chronic venous insufficiency.^{1,2,3,4}

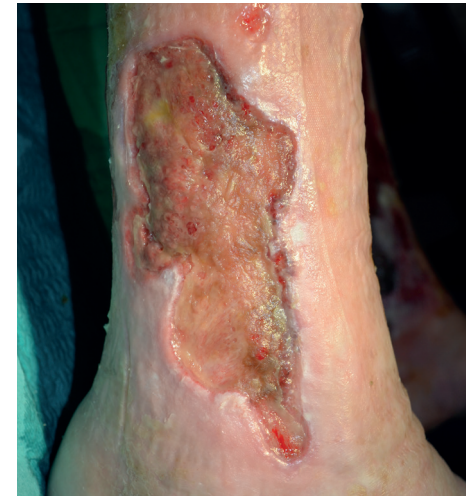Characteristics

A venous leg ulcer usually presents as a shallow ulcer with irregular margins and appears over the area of atrophic and/or pigmented skin. 

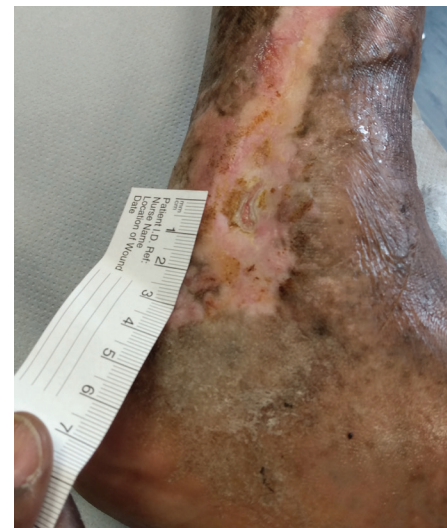What does it look like?



Venous leg ulcer on the lower leg



Venous leg ulcer on the lower leg





Venous leg ulcer on the lower leg

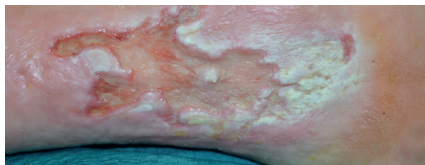

Scan to learn more about
Venous leg ulcers

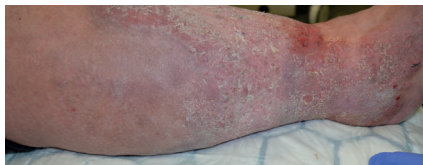Step 1

How to **assess** a venous leg ulcer

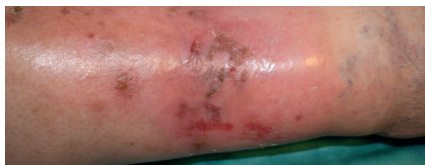- Begin with a holistic patient assessment. 
- Proceed with a lower limb assessment using a validated assessment tool (i.e. Leg Ulcer Measurement Tool LUMT). 
- Then begin your wound assessment using a validated wound assessment tool (i.e. Triangle of wound assessment).
 - Make note of wound size, wound bed, amount and type of exudate, condition of wound edge and periwound skin and signs of infection
 - Also check position of the ulcer – malleolus or gaiter area
- Make your assessment by checking for oedema and looking for:



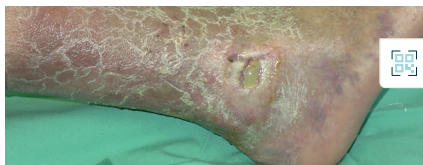Maceration



Stasis dermatitis




Lipodermatosclerosis



Hyperkeratosis

When you are looking for ulceration in a leg, all changes in the skin (including colour and texture should be thoroughly assessed⁵

- Be sure to check for signs of venous insufficiency, by looking for:
 - Oedema – measure circumference of ankle, foot and calf.
 - Signs of vascular insufficiency – inspect arterial flow and perfusion. 
 - Signs of venous hypertension – inspect legs for varicose veins – (reticular phlebectasia), skin changes (i.e. small widened blood vessels (telangiectasia), and changes in pigmentation.



Keep in mind: In the case of venous disease, lipodermatosclerosis and haemosiderin staining are easier to see in pale skin. For patients with dark skin tones feel for the hardening in the skin and compare the affected leg to the other leg for comparison of colour and swelling.⁵

- You should also consider:
 - Patient's BMI (Body Mass Index) – a BMI of between 35-59 is usually when lymphedema occurs⁶
 - Other risks and complicating factors such as: patient mobility, prolonged sitting or standing, calf muscle pump, gait, comorbidities, medications, family history, etc.



Scan to learn more about
LUMT



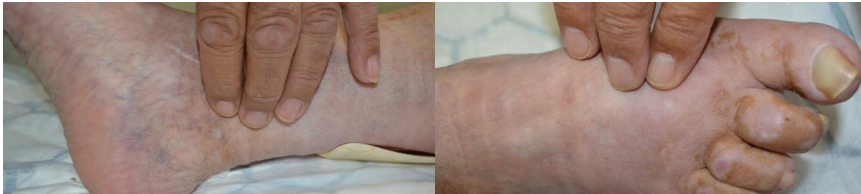Scan to learn more about
Hyperkeratosis of the lower limb



Scan to learn more about
assessing arterial flow and perfusion
(page 5)

How to **diagnose** a venous leg ulcer

- When you are dealing with a venous leg ulcer, it is important to also diagnose the leg to exclude arterial insufficiency.
- Use the ABPIs (Ankle Brachial Pressure Index) as a means of differential diagnosis and to assess the leg for ischemia⁷. (At a minimum, pulse palpation is mandatory – follow local policy)



Explore pulse at multiple locations on ankle and foot without gloves

- Be sure to measure pulse on both locations on the ankle – posterior tibial artery and dorsal pedal artery



Always refer if:


- If you measure no pulse in both locations on the ankle
- If you don't know whether it is venous or arterial ulcer, or an unknown aetiology
- If you are unsure of the diagnosis or the Doppler does not match the presenting signs and symptoms



Keep in mind: People with diabetes can have calcification which means their ABPI can be falsely elevated.⁸ Caution should be exercised with this group. If wave forms on Doppler are biphasic or triphasic and pulse is palpable, it is generally safe to apply compression therapy. In case of ABPI >1.3 or if there are discrepancies between ABPI and clinical signs refer.

Step 2

How to develop a **treatment & care plan**


- Once your diagnosis of the leg has excluded arterial insufficiency, you are ready to determine the need for any additions to the standard treatment planning procedure.
- You should proceed according to the result of your ABPI:
 - In case your ABPI is more than 0.8, arterial involvement can be ruled out and compression therapy  can be considered at 40mmHg.
 - In case your ABPI is between 0.5 and 0.8 refer for advice regarding level of compression.
 - In case your ABPI is less than 0.5 do not compress and refer immediately for vascular assessment.



Scan for
the European Society of Vascular
Surgeons Clinical Practice Guidelines

Step 3

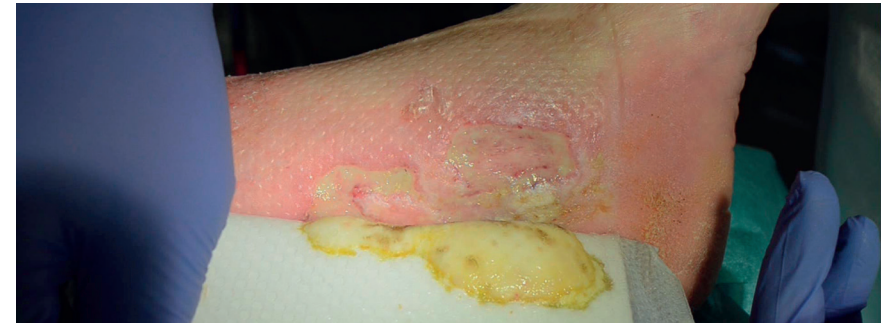How to **manage** a venous leg ulcer

- First, prepare the wound bed by cleansing and debriding the wound to remove debris and necrotic or indolent tissue. Cleansing of the full leg with a pH-appropriate cleanser is recommended to reduce odour and to protect the skin surrounding the ulcer. If possible get the patient to shower.
- Be prepared to manage exudate to protect the periwound skin, as venous leg ulcers are often highly exuding. (This will reduce over time with the correct level of compression therapy).
- Frequently undertake a patient reported pain assessment, as leg ulcers are ranked as the most painful compared to other wounds.²
- Apply compression therapy for patients with active venous ulceration and an ABPI above 0.8 – and refer for vascular assessment and monitoring. (Compression therapy aims to improve venous return and reduce venous hypertension. Compression is usually graduated and can include bandages, wraps, calf pumps and compression hosiery.^{1,8})
- Choose the correct type of compression by taking relevant factors into account: The severity of the disease, the anatomical characteristic of the leg/ankle, required frequency of applications, and the functionality of the patient: Patient preference, mobility, lifestyle and likely concordance.⁹
- Check for signs of infection at each dressing change, as infection and biofilm are common in venous leg ulcers. Use the IWII infection continuum and management guide. 

Step 4

How to **choose dressing** & additional therapy

- Choose a dressing that helps you effectively manage exudate, as venous leg ulcers are typically highly exuding.



- Make sure the dressing is able to conform to the wound. It should leave no gap between dressing and wound bed in order to effectively manage exudate and bacterial balance.
 - For highly exuding wounds consider a superabsorbent dressing.
- Look for dressings that are atraumatic upon removal – it should not cause further damage to the wound bed or periwound skin – but should ideally help decrease pain and odour for patients.
- If you suspect infection use a dressing with antimicrobial properties.
- Consider adjunct therapies like NPWT when appropriate.



Step 5

How to **monitor** progression

- You should monitor venous leg ulcers at least every 4 weeks. Specifically look for distortion or modification of the shape of the leg.
- Measure oedema reduction or redistribution at every dressing change and action taken as needed to amend the compression regime.
- In case, the wound is not healing with therapeutic compression refer to a vascular specialist, if that has not already been done.
- In case ulcer has not healed after 12 weeks, reassess differential diagnosis. Also revisit holistic patient assessment to assess if factors such as low haemoglobin, immune function deficits or other co-morbid conditions are affecting healing. You should also re-consider other risk factors such as patient's lifestyle, past compression usage, etc.
- Discuss prevention strategies with patient such as skin care, life long compression hosiery, physical exercise (ankle & dorsal reflection, gait, calf muscle pump), weight control, etc.

For patients with healed venous leg ulcers, long term compression should be considered to reduce the risk of recurrence. 

When to **refer or contact** a specialist

- ❗ If ABPI is less than 0.8 and patient is symptomatic refer to vascular surgery.
- ❗ If clinical signs and symptoms and Doppler do not match.
- ❗ In the case venous insufficiency is suspected or diagnosed, consider referral to a vascular surgeon to determine if surgical or endovascular therapies are appropriate.
- ❗ If an ulcer has not healed after 12 weeks and reassessment is not conclusive as to why healing is not progressing.
- ❗ If ulcer re-occurs after healing, refer to a vascular specialist.
- ❗ Whenever wounds with an unusual appearance or wounds that appear in unusual locations, fail to respond to appropriate care they should be referred for biopsy to rule out skin cancer.
- ❗ Also refer in case...
 - you detect acute infection of leg or foot (e.g. increasing unilateral redness, swelling, pain, pus, heat)
 - you detect symptoms of sepsis
 - you detect acute or chronic limb threatening ischemia
 - you suspect acute deep vein thrombosis (DVT)
 - you suspect skin cancer
 - you suspect lymphatic involvement



Scan to learn more about
VLU non-healing and recurrence risks

Glossary of venous leg ulcer terms

Venous insufficiency – is a condition in which the veins fail to return blood efficiently to the heart. Symptoms include swelling of the legs and pain in the extremities.

Ischemia – is a lack of blood supply to a certain part of the body, which may cause tissue damage due to lack of oxygen and nutrients.

Oedema – is a build-up of fluid which causes the affected tissue to become swollen and can be localized or more general.

Maceration – occurs when skin is in contact with moisture for too long. Macerated skin looks lighter in colour and wrinkly and may feel soft or soggy to the touch.

Stasis dermatitis – is when there is venous insufficiency, or poor circulation in the lower legs, leading to skin discoloration, pain, itching and sores.

Lipodermatosclerosis – is a chronic inflammatory condition characterised by subcutaneous fibrosis and hardening of the skin on the lower legs.

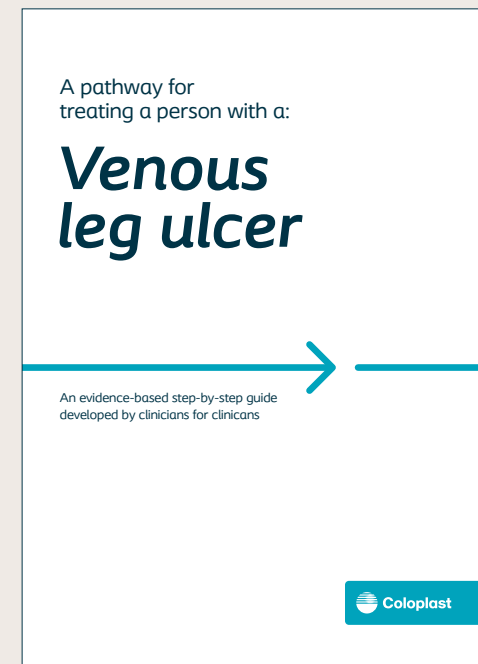
Hyperkeratosis – is a thickening of the skin's outer layer.

Haemosiderin – is a brown iron-containing pigment usually derived from the disintegration of extravasated red blood cells.



Malleolus or gaiter area – the region of the leg located circumferentially around the lower leg from approximately mid-calf to just below the ankle.



For a glossary of general wound care terms consult
The Wound Care Pathway



Hope you found this pathway useful!
For guidance on other **wound types**:





Coloplast A/S, Høtveddam 1
3050 Humlebaek, Denmark